

# A 7-YEAR EXPERIENCE WITH BALLOON-MOUNTED CORONARY STENTS FOR THE TREATMENT OF SYMPTOMATIC VERTEBROBASILAR INTRACRANIAL ATHEROMATOUS DISEASE

## David Fiorella, M.D., Ph.D.

Departments of Neuroradiology and Neurosurgery,  
The Cleveland Clinic Foundation,  
Cleveland, Ohio

## Michael M. Chow, M.D.

Department of Neurosurgery,  
University of Alberta,  
Edmonton, Canada

## Michael Anderson, R.N.

Department of Neurosurgery,  
The Cleveland Clinic Foundation,  
Cleveland, Ohio

## Henry Woo, M.D.

Department of Neurosurgery,  
The Cleveland Clinic Foundation,  
Cleveland, Ohio

## Peter A. Rasmussen, M.D.

Departments of Neuroradiology and Neurosurgery,  
The Cleveland Clinic Foundation,  
Cleveland, Ohio

## Thomas J. Masaryk, M.D.

Departments of Neuroradiology and Neurosurgery,  
The Cleveland Clinic Foundation,  
Cleveland, Ohio

## Reprint requests:

David Fiorella, M.D., Ph.D.,  
Departments of Neuroradiology and Neurosurgery,  
The Cleveland Clinic Foundation,  
9500 Euclid Avenue, S80,  
Cleveland, OH 44195.  
Email: fioreld@ccf.org

Received, June 28, 2006.

Accepted, March 19, 2007.

**OBJECTIVE:** Balloon-mounted coronary stents (BMCS) have been adapted for use in the intracranial circulation for the treatment of symptomatic intracranial atheromatous disease (ICAD). We performed a retrospective analysis of our 7-year experience with these devices in an attempt to quantify the periprocedural risks and long-term outcomes in patients with symptomatic ICAD of the vertebrobasilar (VB) system treated with BMCS.

**METHODS:** A retrospective review of a prospectively maintained database was performed to determine the neurological and non-neurological periprocedural risks of BMCS treatment of ICAD. Patients were followed with serial transcranial Doppler (TCD) and, in some cases, angiographic imaging. The clinical status was determined based on clinic visits and by telephone interviews when possible.

**RESULTS:** Over the 6-year period from March 1999 to May 2005, 44 patients (35 men, 9 women; average age, 64.8 yr) with 47 symptomatic atheromatous lesions of the VB system were treated with BMCS. In two patients, the BMCS could not be delivered across the target lesion. Treatment of the remaining 45 lesions was technically successful (95.7%). The periprocedural neurological morbidity and mortality was 26.1% (10 clinically evident strokes, 2 deaths). One additional patient experienced a periprocedural transient ischemic attack (TIA). Two patients died of non-neurological causes within 6 months (4.3%, myocardial infarction and cholecystitis). The average stenosis measured 82.5%, declining to 10.0% stenosis after BMCS. TCD examinations showed a preprocedural velocity of 127.7 cm/second ( $n = 43$ ; standard deviation, 63.7 cm/s), which declined to 54.0 cm/s immediately after the procedure ( $n = 42$ ; standard deviation, 22.7 cm/s). In patients with serial TCD evaluations, velocities were typically constant over years of follow-up (six patients with  $>5$  yr of follow-up; average velocity, 52.2 cm/s). Angiographic follow-up was available for 11 patients. Three patients had stent occlusion (all symptomatic with TIAs), one patient had greater than 50% in-stent restenosis (ISR) (symptomatic with TIA) and seven had no significant ( $<50\%$ ) stenosis. The overall ISR/occlusion rate was 12.5% (4 out of 32 lesions with angiographic and/or TCD follow-up  $> 6$  mo). Of the 42 patients who successfully underwent BMCS, clinical follow-up was available for 33 (78.6%, average follow-up period, 43.5 mo), three patients died before any follow-up could be performed, and seven were lost to follow-up. Of the patients with follow-up, five had recurrent vertebrobasilar ischemic symptoms (15%; four TIA, one stroke). Four out of five patients with recurrent symptoms had ISR or occlusion verified on conventional angiography. At the time of the last follow-up examination, seven patients of 44 patients who underwent attempted treatment were dead (modified Rankin Scale [mRS] score, 6); four had an mRS score of 3 to 5, 16 had an mRS score of 1 or 2, and 10 had an mRS score of 0.

**CONCLUSION:** Percutaneous transluminal angioplasty and stenting using BMCS for the treatment of symptomatic VB ICAD can be carried out with high rates of technical success and excellent immediate angiographic results. However, the procedure carries with it a very high rate of periprocedural morbidity and mortality. Greater than 50% ISR or stent occlusion occurred in 12.5% of the patients and was associated with recurrent TIAs. In the absence of ISR/occlusion, patients who tolerated the initial procedure did well neurologically and did not typically experience recurrent ischemic symptoms.

**KEY WORDS:** Angioplasty, Balloon-mounted coronary stent, Intracranial atheromatous disease, Stenting

Symptomatic intracranial atheromatous disease (ICAD) has an aggressive natural history with as many as 25% of the patients experiencing new infarcts within 2 years despite the “best” medical therapy (3). For these reasons, endovascular treatment options have been explored as a means of preventing future strokes in this population.

Balloon-mounted coronary stents (BMCS) have been adapted for use in the cerebrovasculature to treat symptomatic ICAD. We report the results of a retrospective analysis of our 7-year experience using BMCS to treat symptomatic ICAD of the vertebrobasilar (VB) system.

## METHODS

We conducted a retrospective analysis of a prospectively maintained database encompassing procedures performed on patients with symptomatic VB ICAD between 1999 and 2005. All patients treated had either failed a trial of medical therapy (including antiplatelet agents, heparin, or warfarin) or had presented with ischemic symptoms while on medical therapy for other vascular disease.

### *Interventional Procedures*

Prior to every procedure, written informed consent was obtained from the patient or his/her family for the intracranial angioplasty and stenting procedure using the available BMCS “off-label” within the cerebrovasculature. All intracranial angioplasty and stenting procedures were performed under general anesthesia. An evolving approach toward anticoagulation and platelet inhibition was evident during the study period. Dual antiplatelet therapy was instituted for at least 3 days before the procedures. This strategy was used for all patients undergoing operation during the final 2 years of data collection. Previously, patients receiving warfarin were either continued on this therapy during the treatment or were converted to heparin for the periprocedural period and then placed back on warfarin after treatment was accomplished. For patients not treated in the context of warfarin therapy, heparin was administered to achieve an activated coagulation time of between 250 and 300 seconds. Abciximab was not routinely administered. Stents used included Velocity (Cordis, Miami, FL), Duet (Guidant, Indianapolis, IN), Tetra (Guidant) and Vision (Guidant). Only one patient required predilation with an angioplasty balloon. All other patients were treated primarily with the BMCS without pre- or postdilation. The sheath was removed immediately after the procedure and hemostasis was achieved with either an Angioseal (St. Jude Medical, St. Paul, MN) or Perclose (Abbott Labs, Chicago, IL). Heparin was not reversed after the procedure. Patients were maintained on dual antiplatelet medications for 6 weeks with aspirin therapy maintained indefinitely thereafter.

Clinical follow-up was performed by the neurointerventionists involved with the primary procedure at 3, 6, and 12 months, and yearly thereafter. In patients with incomplete clinical data, follow-up was performed by phone interview when possible. Transcranial Doppler (TCD) velocities were obtained before treatment, immediately after treatment, at 3, 6, and 12 months, and yearly thereafter. Conventional angiography was performed in patients with recurrent neurological symptoms or TCD evidence of restenosis.

Periprocedural outcome measures included death, permanent neurological morbidity, and all neurological morbidity (including death, permanent, and temporary neurological morbidity). At the time of follow-up, any recurrent or new neurological symptoms referable to the vascular distribution of the treated lesion were recorded. Each patient

was also assigned a modified Rankin Scale (mRS) score at the time of the most recent follow-up evaluation.

## RESULTS

### *Patients*

Over the 6-year period from March 1999 to May 2005, 44 patients (35 men, 9 women; average age, 64.8 yr) with 47 symptomatic atheromatous lesions of the VB system underwent endovascular procedures with the intention of performing percutaneous transluminal angioplasty and stenting (PTAS) using BMCS. Forty-two of the 44 patients had failed medical therapy with antiplatelet agents, anticoagulation, or both; 26 patients had failed anticoagulation therapy with Coumadin (Bristol-Myers Squibb, Princeton, NJ) or heparin; and 36 patients had failed antiplatelet therapy.

### *Periprocedural Results*

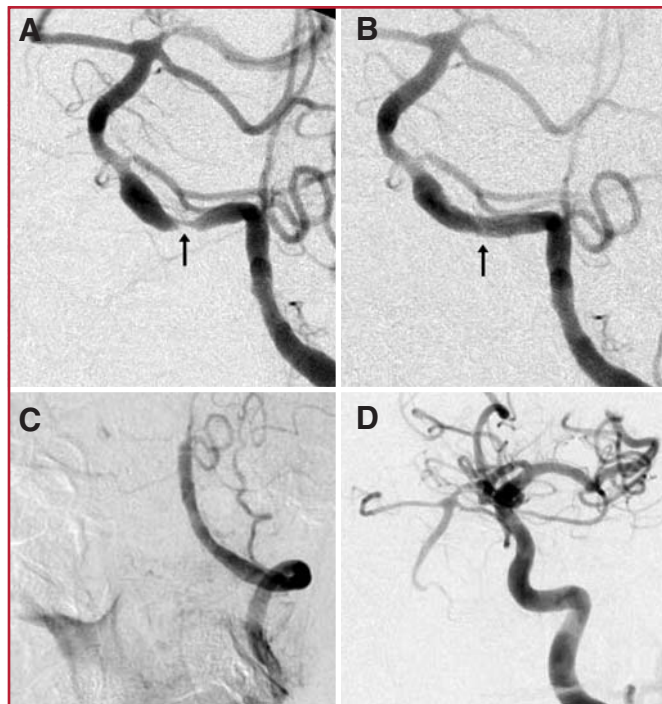
Angioplasty and stenting was successfully performed on 45 of the 47 lesions addressed, resulting in a 95.7% technical success rate. In one patient, treatment was attempted but aborted owing to difficulty navigating the BMCS across the target lesion. This patient underwent angioplasty alone. In a second patient, an intracranial flow limiting dissection precluded stent placement during the attempted navigation of the BMCS to the targeted lesion.

The periprocedural neurological morbidity and mortality rate was 26.1% (nine procedural clinically evident strokes, one postprocedural stroke, and two procedural deaths). The symptomatic procedural strokes were documented by imaging within the pons ( $n = 3$ ), thalamus ( $n = 2$ ), occipital lobe ( $n = 1$ ), medulla ( $n = 1$ ), cervical cord ( $n = 1$ ), and cerebellar hemispheres ( $n = 1$ ). The patient with postprocedural stroke presented 12 days after the stenting procedure with hemorrhagic conversion of a preexisting posterior inferior cerebellar territory infarction and a new left superior cerebellar infarction. The two periprocedural deaths were attributable to an occlusive basilar dissection and a catastrophic subarachnoid hemorrhage, respectively. One additional patient experienced a periprocedural transient ischemic attack (TIA). Two patients died of non-neurological causes within 6 months of the procedure (4.3%, myocardial infarction and cholecystitis/sepsis). The neurological complications were evenly distributed over the course of the series and among the various types of stents used.

The average stenosis measured 82.5% before treatment ( $n = 45$  lesions with films available for review), declining to 10.1% ( $n = 43$  lesions) stenosis after successful BMCS placement (Fig. 1). Of the 47 lesions treated, 40 were more than 70% stenotic and five were between 50 and 69% stenotic; procedural films were unavailable for review in 2 cases.

### *TCD and Conventional Angiographic Imaging*

TCD examination showed an average preprocedural velocity of 128.3 cm/s ( $n = 43$ ; standard deviation, 63.0 cm/s), which declined to 53.0 cm/s immediately after the procedure ( $n = 42$ ; standard deviation, 22.6 cm/s). Although preprocedural TCD



**FIGURE 1.** A 57-year-old man with hypertension, diabetes, hyperlipidemia, and coronary artery disease was admitted for recurrent episodes of dizziness and diplopia. Noninvasive workup demonstrated a high-grade stenosis of the distal V4 segment of the left vertebral artery. These episodes continued despite the institution of dual antiplatelet and heparin therapy. **A**, conventional angiography performed from a left vertebral catheter position demonstrating a high-grade (85%) stenosis of the distal left vertebral artery (black arrow). The right vertebral artery terminated as the posterior inferior cerebellar artery. Single-stage, primary angioplasty and stenting were performed with a Vision 3 mm × 8 mm balloon mounted coronary stent. **B**, after angioplasty and stenting, control angiography performed from the left vertebral artery demonstrated no residual stenosis (0%) in the region of the treated lesion (black arrow). Immediately after the procedure, the ischemic events stopped and the patient was discharged on aspirin and clopidogrel. The patient did well for 1 month but then re-presented with intractable emesis and vertigo. **C**, conventional angiography performed from the left vertebral artery demonstrated occlusion of the stent. **D**, angiography performed from a catheter positioned within the left internal carotid artery demonstrated a small posterior communicating artery, which provided collateral flow to the basilar apex with retrograde reflux into the basilar trunk. Magnetic resonance imaging with diffusion demonstrated evidence of acute infarction. The symptoms resolved over 48 hours.

velocities were typically substantially elevated (>100 cm/s) in the region of the target lesion, the initial TCD velocities were less than 70 cm/s in eight patients. In these eight patients, the lesions were highly stenotic (average, 92.2%; standard deviation, 6.0%). In four of these patients, the velocities actually increased immediately after the procedure. In the other four patients, the immediate postprocedural velocities either stayed the same (n = 1) or decreased only minimally (<5 cm/s, n = 3). Thirty patients had one or more TCD follow-up examination through at least 6 months, and 25 underwent serial TCDs for

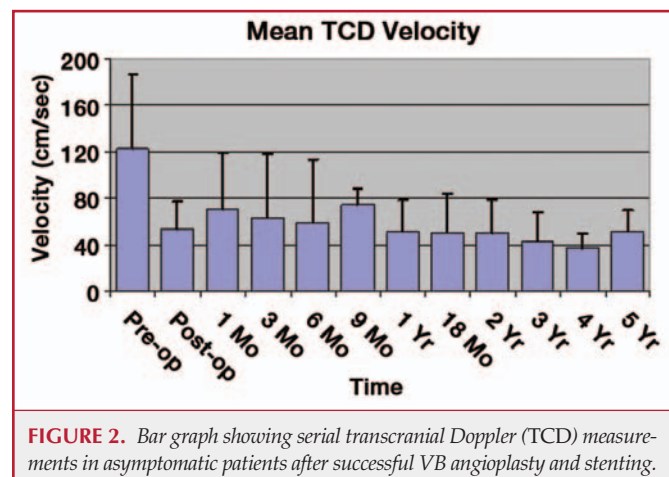
1 year or longer. In patients without recurrent symptoms, serial TCD values remained stable throughout the duration of the follow-up period (Fig. 2).

Angiographic follow-up (range, 1–54 mo; average, 20.5 mo) was available for 11 patients and was performed for either recurrent symptoms, elevated TCD velocities, or in the context of angiography being performed for a different procedure (e.g., carotid stenting). Three patients had stent occlusion (all symptomatic with TIAs), one patient had greater than 50% in-stent restenosis (ISR) symptomatic with TIA (Fig. 3), and seven had no significant ISR. One of the patients without ISR on angiographic follow up developed a new focus of high-grade stenosis several centimeters proximal to the stented basilar artery (within the right vertebral artery), which was identified when they presented with a new posterior circulation stroke. A second patient undergoing angiography for increased TCD velocities demonstrated asymptomatic progression of a vertebral artery stenosis proximal to the stented lesion (at the vertebrobasilar junction). Thirty-two lesions were studied with TCD or conventional angiography for at least 6 months, yielding an overall ISR/occlusion rate of 12.5%.

Nine patients in the current series had both TCD and angiographic follow-up. Correlation was excellent in seven of the nine patients with TCD correctly predicting the presence or absence of ISR. In one patient, ISR was suspected on the basis of elevated TCD velocity (130 cm/s). However, conventional angiography demonstrated no significant ISR. Of note, this patient also demonstrated relatively high immediate posttreatment baseline velocities (97 cm/s). The subsequent measurement performed 2 years later was essentially equivalent to the immediate postprocedural measurement (102 cm/s). In another patient, TCD indicated markedly increased velocities within the stented vessel, whereas correlative conventional angiography demonstrated stent occlusion.

#### Clinical Follow-up

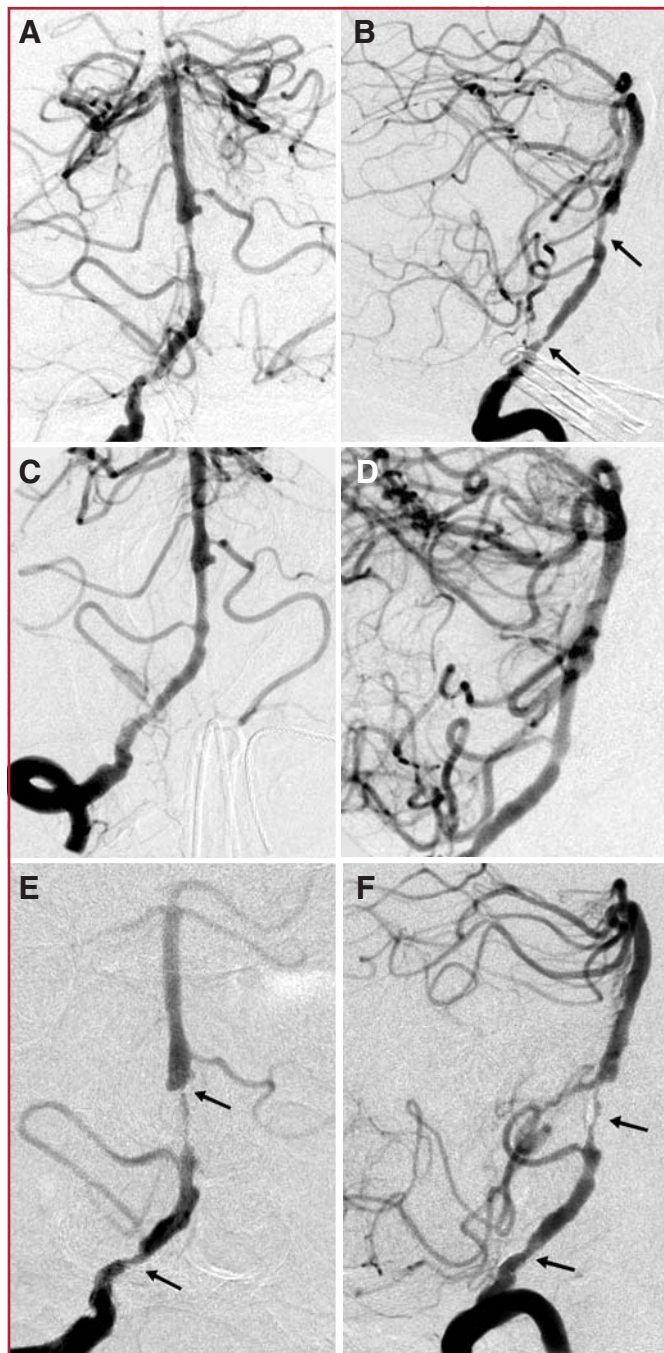
Of the 42 patients who successfully underwent BMCS, clinical follow-up was available for 33 (78.6%, average follow-up



**FIGURE 2.** Bar graph showing serial transcranial Doppler (TCD) measurements in asymptomatic patients after successful VB angioplasty and stenting.



period, 43.5 mo), two patients died before follow-up could be performed, and seven were lost to follow-up. Of the patients with follow-up, five had recurrent symptoms (15%; four TIA, one stroke). Four of the five patients with recurrent symptoms (all with TIAs) had ISR or stent occlusion verified on conventional angiography (Figs. 1 and 3). The patient presenting with ipsilateral stroke 16 months after the procedure demonstrated no ISR but had developed a high grade right vertebral stenosis several centimeters proximal to the stented basilar artery lesion.



At the time of the most recent follow-up examination, seven patients were dead (mRS score, 6), four had an mRS score of 3 to 5, 16 had an mRS score of 1 or 2, and 10 had an mRS score of 0. Of the seven patients who died, two died as a result of complications during or immediately after the procedure, two died less than 6 months after the procedure of unrelated causes (myocardial infarction and acute cholecystitis), and three died of undetermined causes. Excluding the procedural deaths, the average time of death was 32.4 months (range, 1–77 mo). All four patients who had mRS scores of 3 to 5 were disabled as a result of their presenting infarcts; none had experienced procedural complications and three of the four were without new ischemic events after stenting. The one patient who sustained a new stroke months after the stenting procedure did not change in mRS score after the event.

Of the 10 patients who experienced nonfatal, clinically evident periprocedural infarcts, six were in good or excellent neurological condition (mRS score 2,  $n = 3$ ; mRS score 1,  $n = 2$ ; mRS score 0,  $n = 1$ ; follow-up period, 27–59 mo; average follow-up duration, 40.8 mo), two were deceased, and two were lost to clinical follow-up.

## DISCUSSION

Open surgical or endovascular strategies for the treatment of patients with symptomatic ICAD must satisfy two criteria: reasonable safety and long-term efficacy. Ultimately, the periprocedural morbidity and mortality in combination with the post-procedural stroke rate must compare favorably with the natural history of the disease process in the context of the “best” medical therapy.

The results of the recent Warfarin-Aspirin Symptomatic Intracranial Disease (WASID) study indicate that patients with

**FIGURE 3.** A 72-year-old woman with multiple posterior circulation strokes, hyperlipidemia, diabetes, and coronary artery disease presented with crescendo TIAs (10–12 per day) while on aspirin and warfarin. Conventional angiography performed from a catheter position within the right vertebral artery in the transfacial (A) and lateral (B) projections demonstrated an irregular long segment stenosis of the midbasilar artery and a more proximal stenosis of the V4 segment of the right vertebral artery. The right vertebral artery was dominant, and the left vertebral artery was diminutive with a high-grade origin stenosis and multiple tandem intracranial stenoses. Angioplasty and stenting were performed via a transradial approach with a  $2.5 \times 12$  mm Multilink Vision (Guidant) placed within the basilar artery and a  $2.5 \times 8$  mm Multilink Vision placed within the distal V4 segment of the right vertebral artery. Poststenting angiography in the transfacial (C) and lateral (D) projections demonstrated significant improvement of the basilar and vertebral stenoses. Immediately after the procedure, the TIAs resolved. The preprocedural basilar velocity was 152 cm/s, declining to 102 cm/s after the procedure. The patient did well neurologically after the procedure but then experienced a recurrence of her TIAs. TCD demonstrated increased velocity within the basilar artery (191 cm/s). Conventional angiography in the transfacial (E) and lateral (F) projections demonstrated severe basilar in-stent restenosis (95%, black arrow) and less severe restenosis within the proximal right vertebral stent (black arrow).

high-grade intracranial stenosis presenting with stroke are at a high risk (approximately 25% over 2 yr) for subsequent stroke despite the “best” medical therapy (3, 8). These patients represent the group with the greatest potential to benefit from revascularization procedures.

We constructed a prospectively maintained database of symptomatic VB stenoses to allow us to evaluate the safety, efficacy, and durability of PTAS using BMCS. The database was limited to VB stenoses for several reasons. First, all operators at our institution followed a uniform approach to the treatment of these lesions, namely single-stage, primary PTAS with BMCS. Secondly, the literature predating the WASID study indicated that the natural history of symptomatic lesions of the VB system was particularly malignant in comparison with other intra- and extracranial stenoses (13, 14). Finally, strokes occurring in this distribution are frequently fatal or neurologically devastating (15). The latter two factors support aggressive therapy in selected patients, e.g., those with high-grade symptomatic stenosis refractory to medical therapy.

### Treatment of Symptomatic Vertebrobasilar ICAD with BMCS: A Viable Treatment Option?

#### *Periprocedural Morbidity*

In the current series, we observed a high (26.1%) rate of major periprocedural morbidity and mortality relative to the natural history of the disease. Essentially, the patients treated with primary, single-stage angioplasty and stenting with the balloon-mounted coronary stents used in this series were exposed to an “up front” periprocedural risk that equaled or exceeded that of the natural history of the disease treated with medical therapy over a 2-year period. The periprocedural risks observed in the current study are similar to those reported in other smaller studies (9, 10, 17, 18). In this setting, even if the risk of subsequent ipsilateral territory stroke was completely eradicated by the procedure, the viability of the procedure as a treatment option is still doubtful. Particularly considering that these patients are frequently older and have significant comorbidities that may reduce their lifespan and thus limit the duration of time they have to benefit from a cerebral revascularization procedure. In addition, the cost of the procedure represents an important consideration if the efficacy is marginal.

The morbidity associated with PTAS using BMCS is related not only to the disease process, but also to the physical characteristics of the available coronary devices adapted for intracranial use. Although the devices went through several iterations over the course of the study, the BMCS remained relatively inflexible and difficult to navigate through the tortuous cerebrovasculature. To support the navigation of these stents, aggressive guide catheter access was necessary within the parent vessel leading to the target lesion. Distal parent vessel catheterization with stiff, large bore, guiding catheters and sheaths frequently resulted in parent vessel trauma leading to spasm and sometimes dissection. Distal access with stiff exchange length microwires was also required to support the delivery of these inflexible stents to and across the intracranial

stenotic lesions. The distal passage of these stiff exchange microwires into the posterior cerebral arteries can substantially deform these small intracranial vessels, producing vasospasm and exposing these delicate vessels to a potential risk of dissection and perforation. Once delivered across the stenosis, the stents are deployed via the inflation of a high-pressure angioplasty balloon, inducing significant vascular trauma with the risks of plaque rupture and distal embolization in addition to the potential for vessel rupture. To achieve good stent apposition over the entire length of the vessel and to free the stent of the angioplasty balloon, an aggressive angioplasty was required with dilation of the lesion to a diameter approaching that of the normal parent vessel. Underinflation of the angioplasty balloon increases the odds of an incomplete stent release from the balloon with the risk of dragging the stent back through the lesion during the attempted removal of the angioplasty catheter. At the same time, gross undersizing of the stent risks poor apposition of the stent to the distal and proximal parent vessel, creating an environment for turbulent flow and the generation of thromboemboli.

#### *Efficacy in Stroke Prevention*

After successful PTAS, few patients (15%) experienced recurrent symptoms and only one patient (3%) experienced a stroke within the ipsilateral vascular territory. Four of the five patients with recurrent symptoms had ISR or stent occlusion, and all four patients with ISR/occlusion presented with recurrent symptoms. These results indicate that patients with successful and durable revascularization have very low rates of recurrent events; none of the patients without either ISR/occlusion or a new focus of VB stenosis experienced recurrent ischemic symptoms, whereas all patients with these problems did.

Although ISR/occlusion resulted in recurrent neurological symptoms and sometimes necessitated retreatment (Fig. 3), this phenomenon was not a major contributor to permanent morbidity in this population. The present data clearly indicate that periprocedural morbidity, not delayed ISR/occlusion, is the major downfall of BMCS as an effective strategy for the treatment of symptomatic ICAD. Correspondingly, better and safer devices or improved techniques designed to reduce periprocedural morbidity will be required before intracranial angioplasty and stenting can represent a viable treatment option for these patients. The recent enthusiasm surrounding the potential adaptation of drug-eluting coronary stents for use in the cerebrovasculature, represents a solution which fails to address the primary problem of periprocedural morbidity (1).

#### *Outcomes of Patients with Periprocedural Stroke*

Most patients who experienced periprocedural strokes (six out of eight with follow-up) improved significantly after their event, went on to good or excellent clinical outcomes, and were free of future events. This represents an interesting caveat of the current study, as one could hypothesize that the periprocedural events encountered during therapy may be less significant if patients subsequently make substantial recoveries and are without recurrent stroke thereafter. Unfortunately, the pub-

lished WASID data do not address the long-term outcomes of those patients who experienced stroke during the course of the trial while on medical therapy. As such, no comparative analysis with a medically treated group is possible.

#### *Utility of TCD as a Follow-up Study*

In most cases, immediate postprocedural TCD examinations demonstrated a significant decline in flow velocities across the treated lesion. In very highly stenotic lesions (>90%), the preprocedural velocities were occasionally normal or only minimally elevated with the immediate postprocedural TCD examinations in some cases actually demonstrating flow velocity increases after the procedures.

In patients without recurrent symptoms, serial TCD values typically remained stable over years of follow-up. In most cases with conventional angiographic follow-up, correlation with TCD was excellent. None of the patients demonstrated ISR or occlusion in the setting of stable TCD values.

We currently use TCD as a noninvasive screening modality with which to follow patients after angioplasty and stenting. Conventional angiography is reserved for patients with a change in TCD velocities from posttreatment baseline or new symptoms.

#### *Alternative Therapeutic Options for Symptomatic ICAD*

Given the limitations of BMCSs for the treatment of symptomatic ICAD, other therapeutic options should be considered for these patients. Several strategies, both surgical and endovascular, have been evaluated to date.

The extracranial-intracranial bypass trial evaluated the efficacy of surgical bypass for the treatment of symptomatic carotid occlusive disease. This study included a subset of patients with symptomatic middle cerebral artery stenosis ( $n = 109$ ) or occlusion ( $n = 159$ ). Of all of the patients in the extracranial-intracranial bypass trial, patients with severe middle cerebral artery stenosis fared the worst after surgical bypass therapy ( $\chi^2 = 4.74$ ) with an incidence of fatal and nonfatal stroke (22 out of 50 patients, 40%) nearly double that of the medical therapy group (14 out of 59, 23.7%). On the basis of these data, surgical bypass is generally recognized as a suboptimal treatment strategy in this group of patients. Furthermore, bypass for VB atheromatous disease, as addressed in the current series, is a more technically demanding and morbid procedure without evidence to support its efficacy (7).

In addition to BMCS deployment, various endovascular strategies have been applied to the revascularization of patients with symptomatic ICAD. Until the recent introduction of the Gateway balloon-Wingspan self-expanding stent system (Boston Scientific, Natick, MA), these strategies were limited to percutaneous transluminal angioplasty (PTA) alone and PTAS using a balloon-mounted stent designed for use in the cerebrovasculature (Neurolink, Guidant).

Neurolink was evaluated in the multicenter Stenting of Symptomatic Atherosclerotic Lesions in the Vertebral or Intracranial Arteries trial, during which the stent was used to treat both intra- and extracranial vertebral artery stenoses.

These authors reported a 6.6% rate of periprocedural stroke and an additional stroke rate of 7.3% between 30 days and 1 year (16). With respect to the intracranial lesions treated, these authors reported a 14% (6 out of 43) overall (periprocedural and postprocedure) rate of stroke at 1 year. Despite these promising initial results, the Neurolink stent is not commercially available. As such, we will limit our discussion of alternative therapies to angioplasty alone and PTAS with the Gateway-Wingspan system.

The initial intracranial angioplasty series reported relatively high levels of periprocedural morbidity and mortality. For example, Gress et al. (5) reported a 28% stroke/death complication rate in a series of 25 patients with vertebrobasilar ICAD treated at the University of California, San Francisco. However, these initial procedures were performed without "modern" dual antiplatelet therapy, and treatment was often performed without any antiplatelet therapy. In addition, significant advances in the angioplasty technique were described by Connors and Wojak (4). These techniques, which involved the use of an undersized angioplasty balloon and a very slow balloon inflation rate (1 atm/min), considerably lowered the periprocedural complications associated with PTA. More recent single institution series of intracranial angioplasty without stenting confirm that this procedure can be performed with an acceptable risk profile. Marks et al. (11) presented a retrospective analysis of 36 patients with symptomatic ICAD who underwent PTA. These authors reported two procedural deaths and one symptomatic reperfusion hemorrhage. Of the 34 patients with clinical follow-up (average, 52.9 mo), two experienced ipsilateral strokes. Overall, the patients treated in this series had an 84.7% ipsilateral stroke-free survival rate. More recently, Marks et al. combined this data with other investigators and composed a multicenter retrospective experience that included 120 patients with 124 treated lesions (12). These investigators reported a 5.8% rate of stroke and death within 30 days of the procedure with an additional 5.2% of the patients experiencing a recurrent stroke during the long-term follow-up period (average, 42.3 mo). When considered in the context of the WASID study (3, 8), these data support angioplasty as a viable alternative to medical therapy for selected patients with symptomatic ICAD, particularly those with high-grade stenosis (>70%) presenting with stroke.

The Gateway balloon-Wingspan stent system was introduced for humanitarian device exemption use in the United States in November of 2005. Correspondingly, very little data are available regarding the safety profile and efficacy of the system. Wingspan is a flexible, self-expanding, microcatheter-delivered, microstent designed specifically to reduce the periprocedural morbidity of intracranial PTAS. The flexible, low profile, stent system is delivered across the lesion over a floppy microwire after the lesion has been dilated with an intermediate pressure (approximately 6 atm) angioplasty technique with an undersized angioplasty balloon (80% of the estimated normal vessel diameter). Henkes et al. (6) performed this procedure on 15 patients with symptomatic ICAD with only one transient periprocedural ischemic event and



no recurrent TIAs or strokes in the treated patients during 1 month of follow-up. These data were incorporated into a larger European-Asian Wingspan stent trial that included 43 patients with medically refractory intracranial atherosclerotic disease. The Wingspan system was used to treat these patients with an overall rate of ipsilateral stroke and death of 7% (three out of 43 patients) over 6 months (2).

Currently, PTAS alone and possibly PTAS with the Wingspan system seem to represent viable therapeutic options for patients with symptomatic ICAD. When more safety and efficacy data are available for the Wingspan system, it is possible that one or both of these strategies will prove potentially superior to medical therapy. Ultimately, this determination will require a multicenter randomized trial of intervention versus medical therapy.

The current study has several important limitations. First, the total number of patients is still relatively small and the conclusions drawn from the current data set may not be universally applicable. Second, a significant number (23%) of patients were lost to follow-up, introducing some uncertainty into the estimates of procedural efficacy for the prevention of recurrent ischemic symptoms and stroke. Finally, the current series represents a retrospective review of a prospectively maintained single-institution database, with the adjudication of complications based upon the impression of the operators and the available clinical documentation, which is subject to an inherent level of bias.

## SUMMARY

PTAS for the treatment of symptomatic VB ICAD can be carried out using BMCS with high rates of technical success and excellent immediate angiographic results. However, the procedure carries with it a very high rate of periprocedural morbidity and mortality (26.1%), which represents the primary limitation of this modality for the treatment of ICAD. Greater than 50% ISR or stent occlusion occurred in 12.5% of patients and was associated with recurrent, but typically transient, ischemic symptoms. In the absence of ISR/occlusion, almost all patients who tolerated the initial procedure did well neurologically and did not typically experience recurrent ischemic symptoms.

## REFERENCES

1. Abou-Chebl A, Bashir Q, Yadav JS: Drug-eluting stents for the treatment of intracranial atherosclerosis: Initial experience and midterm angiographic follow-up. *Stroke* 36:e165-e168, 2005.
2. Bose A: Theory and new technology for improving interventional therapy for intracranial atherosclerotic disease: Full results from the Wingspan HDE safety study. Presented at the American Society of Neuroradiology Annual Meeting, Toronto, Canada, May 23, 2005.
3. Chimowitz MI, Lynn MJ, Howlett-Smith H, Stern BJ, Hertzberg VS, Frankel MR, Levine SR, Chaturvedi S, Kasner SE, Benesch CG, Sila CA, Jovin TG, Romano JG; Warfarin-Aspirin Symptomatic Intracranial Disease Trial Investigators: Comparison of warfarin and aspirin for symptomatic intracranial arterial stenosis. *N Engl J Med* 352:1305-1316, 2005.
4. Connors JJ 3rd, Wojak JC: Percutaneous transluminal angioplasty for intracranial atherosclerotic lesions: evolution of technique and short-term results. *J Neurosurg* 91:415-423, 1999.
5. Gress DR, Smith WS, Dowd CF, Van Halbach V, Finley RJ, Higashida RT: Angioplasty for intracranial symptomatic vertebrobasilar ischemia. *Neurosurgery* 51:23-29, 2002.
6. Henkes H, Milosavski E, Lowens S, Reinartz J, Liebig T, Kuhne D: Treatment of intracranial atherosclerotic stenoses with balloon dilatation and self-expanding stent deployment (Wingspan). *Neuroradiology* 47:222-228, 2005.
7. Hopkins LN, Budny JL: Complications of intracranial bypass for vertebrobasilar insufficiency. *J Neurosurg* 70:207-211, 1989.
8. Kasner SE, Chimowitz MI, Lynn MJ, Howlett-Smith H, Stern BJ, Hertzberg VS, Frankel MR, Levine SR, Chaturvedi S, Benesch CG, Sila CA, Jovin TG, Romano JG, Cloft HJ; Warfarin Aspirin Symptomatic Intracranial Disease Trial Investigators: Predictors of ischemic stroke in the territory of a symptomatic intracranial arterial stenosis. *Circulation* 113:555-563, 2006.
9. Kessler IM, Mounayer C, Piotin M, Spelle L, Vanzin JR, Moret J: The use of balloon-expandable stents in the management of intracranial arterial diseases: A 5-year single-center experience. *AJNR Am J Neurorad* 26:2342-2348, 2005.
10. Levy EI, Horowitz MB, Koebe CJ, Jungreis CC, Pride GL, Dutton K, Purdy PD: Transluminal stent-assisted angioplasty of the intracranial vertebrobasilar system for medically refractory, posterior circulation ischemia: Early results. *Neurosurgery* 48:1215-1221, 2001.
11. Marks MP, Marcellus ML, Huy MD, Schraedley-Desmond PK, Steinberg GK, Tong DC, Albers GW: Intracranial angioplasty without stenting for symptomatic atherosclerotic stenosis: long-term follow-up. *AJNR Am J Neuroradiol* 26:525-530, 2005.
12. Marks MP, Wojak JC, Al-Ali F, Jayaraman M, Marcellus ML, Connors JJ, Do HM: Angioplasty for symptomatic intracranial stenosis: clinical outcome. *Stroke* 37:1016-1020, 2006.
13. Marzewski DJ, Furlan AJ, St Louis P, Little JR, Modic MT, Williams G: Intracranial internal carotid artery stenosis: long-term prognosis. *Stroke* 13:821-824, 1982.
14. Moufarrij NA, Little JR, Furlan AJ, Leatherman JR, Williams GW: Basilar and distal vertebral artery stenosis: Long-term follow-up. *Stroke* 17:938-942, 1986.
15. Pessin MS, Gorelick PB, Kwan ES, Caplan LR: Basilar artery stenosis: Middle and distal segments. *Neurology* 37:1742-1746, 1987.
16. SSYLIVIA Study Investigators: Stenting of Symptomatic Atherosclerotic Lesions in the Vertebral or Intracranial Arteries (SSYLIVIA): Study results. *Stroke* 35:1388-1392, 2004.
17. Weber W, Mayer TE, Henkes H, Kis B, Hamann GF, Schulte-Altdorneburg G, Brueckmann H, Kuehne D: Stent-angioplasty of intracranial vertebral and basilar artery stenoses in symptomatic patients. *Eur J Rad* 55:231-236, 2005.
18. Yu W, Smith WS, Singh V, Ko NU, Cullen SP, Dowd CF, Halbach VV, Higashida RT: Long-term outcome of endovascular stenting for symptomatic basilar artery stenosis. *Neurology* 64:1055-1057, 2005.

## COMMENTS

Fiorella et al. describe their 7-year experience treating 44 patients with symptomatic atherosclerotic lesions of the vertebrobasilar (VB) system using balloon-mounted coronary stents (BMCS). As the authors alluded, the periprocedural technical success rate was approximately 96% and has been reported previously; the periprocedural neurological morbidity and mortality was approximately 26.1% with 10 clinical strokes and two deaths occurring as a result of the treatment. One additional patient experienced a periprocedural transient ischemic attack. Using transcranial Doppler methodology, they demonstrated that the hemodynamic lesion had been reversed. Ten patients were lost to follow-up and, obviously, we have no way of knowing what transpired in these individuals. At a minimum, the periprocedural neurological morbidity and mortality was 26%.

What is extremely important in this analysis is that the data demonstrates that the rate limiting factor for long-term success was the periprocedural morbidity and was not related to either intrastent stenosis or delayed occlusion. Considering the natural history of this disease if left untreated, if the periprocedural risks can be lowered to an accept-

able level, as has been demonstrated from some preliminary unpublished data regarding the Wingspan stent (Boston Scientific, Natick, MA), I am confident that this type of treatment will replace medical therapy, which has been shown to be ineffective in reducing long-term risk of stroke resulting from intracranial atherosclerotic disease. In addition, drug-eluting stents may also reduce the incidence of intrastent restenosis and occlusion.

I congratulate the authors for their careful analysis of their findings and their contribution to the fact that this treatment is effective in reducing the risk of long-term stroke for intracranial atherosclerotic disease of the VB system if the periprocedural morbidity and mortality can equally be reduced.

**Robert H. Rosenwasser**  
*Philadelphia, Pennsylvania*

**F**iorella et al. report 44 patients with 47 symptomatic atheromatous lesions of the VB system that were treated with BMCS. The technical success rate was 95.7%, and the average angiographic stenosis of 82.5% declined to 10.1% after stent placement. On the other hand, a high rate of periprocedural morbidity and mortality (26.1%) was encountered.

The authors thoroughly describe disadvantages and possible risks of BMCS placement and mention the Gateway balloon-Wingspan stent system as a potential optimal option for symptomatic intracranial atheromatous disease. Although the number of patients in the current series is not large and angiographic follow-up data is available for only 11 patients, this article clearly presents practical problems associated with BMCS placement for symptomatic atheromatous VB system disease and contributes to the literature on endovascular treatment of VB intracranial atheromatous disease.

**Junichi Yamamoto**  
**L. Nelson Hopkins**  
*Buffalo, New York*

**F**iorella et al. provide us with another evaluation of intracranial stenting, this time a retrospective review of BMCS used off-label for symptomatic VB atheromatous disease. Over a 7-year period, 44 patients were treated with a high degree of stent-deployment success; however, the periprocedural morbidity and mortality were significant in 26.1% of the cases. Additionally, angiographic follow-up data were limited and only 11 patients were evaluated. Despite these low numbers, the findings were alarming with three occluded vessels and one with greater than 50% stenosis. Fifteen percent of patients with clinical follow up had recurrent VB symptoms; three patients died.

It is difficult to draw any specific comparisons between these data and the limited information available for the currently available self-expanding stent devices. The Stenting of Symptomatic Atherosclerotic Lesions in the Vertebral or Intracranial Arteries Trial resulted in the product not being released commercially. Referring physicians and neuroendovascular therapists should look very carefully at these reports and, as the authors suggest, support the development of a prospective randomized evaluation of medical therapy versus intracranial endovascular therapy.

**Sean D. Lavine**  
*New York, New York*

**T**he authors have presented the largest series of angioplasty and stenting in the intracranial VB territory. Nearly all patients (42 out of 44) had failed medical therapy (antiplatelets, anticoagulation, or both). With the presumed poor natural history in these patients, it was reasonable to explore the use of stenting as a treatment option. The authors are to be congratulated on their honest assessment of this procedure. With a 26.1% procedural complication rate and the current knowledge of the natural history from the Warfarin-Aspirin Symptomatic Intracranial Disease study publications, they rightly state that using the coronary stent systems for this disease is untenable (2, 3).

However, although the numbers are small, there is some tantalizing data hidden in this study. If the rate of stroke after a successful procedure is very low (reported at 3%, with the remainder of evaluable patients having transient ischemic attacks only), we should examine the aspects of this procedure that contribute to longer-term stroke reduction risk. Only short-term data has been presented for the Wingspan stent, but even it shows a higher 7% ipsilateral stroke rate at 6 months (1). However, with 23% of patients lost to follow up in this current study, there is the possibility that the long-term stroke risk is as high or higher than that seen in the Wingspan and Warfarin-Aspirin Symptomatic Intracranial Disease trials (1, 3). Also, case series of angioplasty alone have shown much lower rates of procedural complications. Perhaps strategies that utilize the successful aspects of each therapy will be necessary to lower the procedural risk while maintaining a lower long-term risk of stroke compared to medical therapy.

There is other information that would be important to explore. It would be interesting to map out the rate of complications by year for this study. Certainly, there were technical advances in the wires, stents, and balloons used, and the operator experience increased throughout the course of the study. Possibly, the numbers are too small to achieve meaningful results. Also, over the 7-year period, there were 44 patients; in a busy institution, this may indicate that the authors were selective in choosing which patients to treat. Tortuosity, proximal vessel disease, and the anatomic characteristics of the lesions themselves have a great impact on the risk profile of this treatment. In order to implement this therapy, selection both by medical and anatomic factors is likely necessary. These and many other questions remain. As the authors state, we will ultimately need a randomized trial.

**Gary Duckwiler**  
*Los Angeles, California*

1. Bose A, Hartmann M, Henkes H, Liu HM, Teng MM, Szikora I, Berlis A, Reul J, Yu SC, Forsting M, Lui M, Lim W, Sit SP: A novel, self-expanding, nitinol stent in medically refractory intracranial atherosclerotic stenoses: The Wingspan study. *Stroke* 38:1531-1537, 2007.
2. Chimowitz MI, Lynn MJ, Howlett-Smith H, Stern BJ, Hertzberg VS, Frankel MR, Levine SR, Chaturvedi S, Kasner SE, Benesch CG, Sila CA, Jovin TG, Romano JG; Warfarin-Aspirin Symptomatic Intracranial Disease Trial Investigators: Comparison of warfarin and aspirin for symptomatic intracranial arterial stenosis. *N Engl J Med* 352:1305-1316, 2005.
3. Kasner SE, Chimowitz MI, Lynn MJ, Howlett-Smith H, Stern BJ, Hertzberg VS, Frankel MR, Levine SR, Chaturvedi S, Benesch CG, Sila CA, Jovin TG, Romano JG, Cloft HJ; Warfarin-Aspirin Symptomatic Intracranial Disease Trial Investigators: Predictors of ischemic stroke in the territory of a symptomatic intracranial arterial stenosis. *Circulation* 113:555-563, 2006.